



Six-month Efficacy of Perineural Dextrose for Carpal Tunnel Syndrome: A Prospective, Randomized, Double-Blind, Controlled Trial

Yung-Tsan Wu, MD; Tsung-Yen Ho, MD; Yu-Ching Chou, PhD; Ming-Jen Ke, MD; Tsung-Ying Li, MD; Chia-Kuang Tsai, MD; and Liang-Cheng Chen, MD

Abstract

Objective: To assess the 6-month effectiveness of ultrasound-guided perineural injection therapy (PIT) using 5% dextrose (D5W) in patients with mild-to-moderate carpal tunnel syndrome (CTS).

Patients and Methods: A prospective, randomized, placebo-controlled, and double-blind study was conducted between May 1, 2016, through March 30, 2017. A total of 49 participants diagnosed with mild-to-moderate CTS were randomized into D5W and control groups. Participants in the D5W group received 1 session of ultrasound-guided PIT with 5 cc of D5W, and the control group received PIT with normal saline. The visual analog scale measured pain as a primary outcome. Secondary outcomes were Boston Carpal Tunnel Syndrome Questionnaire scores, the cross-sectional area of the median nerve, and electrophysiological measurement results. Assessment was performed before injection and at 1, 3, and 6 months post-injection.

Results: All patients (data from 30 wrists in each group) completed the study. Compared with the control group, at all post-injection time points, the D5W group had a significant reduction in pain and disability, improvement on electrophysiological response measures, and decreased cross-sectional area of the median nerve.

Conclusion: Our study reveals that ultrasound-guided PIT with D5W is an effective treatment for patients with mild-to-moderate CTS.

Trial Registration: www.ClinicalTrials.gov: NCT02809261.

© 2017 Mayo Foundation for Medical Education and Research ■ Mayo Clin Proc. 2017;92(8):1179-1189

Carpal tunnel syndrome (CTS) is the most common focal entrapment neuropathy.

The etiology of CTS is unknown, but generally, it is believed to result from nerve damage resulting from compression of the median nerve (MN) in carpal tunnel–related gradual ischemia.^{1,2} Therapeutic strategies for CTS range from conservative treatments (eg, medication, splinting, corticosteroid injection, and extracorporeal shock wave therapy) to surgical intervention. Although conservative approaches are beneficial for most patients who have mild-to-moderate CTS,³ a large, population-based study reported that approximately 40% of conservatively treated patients sustained symptoms after 30 months.⁴ Moreover, a Cochrane review⁵ indicates that the effectiveness of conservative treatments is only short term; hence, development of new approaches for conservative management of mild-to-moderate CTS is critical.

Perineural injection therapy (PIT) is a novel technique that involves the injection of dextrose solutions into the peripheral nerve and has been found to provide promising pain-relief benefits.⁶⁻⁸ Notably, 5% dextrose (D5W) has an osmolality similar to that of normal saline, and on injection is less painful than sterilized water.⁹ Moreover, human and animal studies have found that D5W is not harmful to nerves.⁹⁻¹² In addition, D5W, unlike solutions of more than 10% dextrose, is useful in prolotherapy, a term that refers to treatment of various conditions associated with musculoskeletal pain.^{13,14} Currently, in clinical practice, D5W is the most commonly used solution for PIT. However, few studies have investigated the efficacy of PIT for pain relief. Ultrasound-guided PIT, using corticosteroid in combination with lidocaine, is a treatment for releasing entrapments of the peripheral nerves, such as the MN,^{15,16} the ulnar



For editorial comment, see page 1173

From the Department of Physical Medicine and Rehabilitation (Y.-T.W., T.-Y.H., M.-J.K., T.-Y.L., L.-C.C.), Integrated Pain Management Center (Y.-T.W., T.-Y.L.), Department of Neurology (C.-K.T.), Tri-Service General Hospital, School of Medicine; Graduate Institute of Medical Science (C.-K.T.), School of Medicine; and School of Public Health (Y.-C.C.), National Defense Medical Center, Taipei, Taiwan, Republic of China.

nerve,¹⁷ the lateral femoral cutaneous nerve,^{18,19} the saphenous nerve,²⁰ and the sural nerve.²¹ Although use of ultrasound-guided PIT in the clinical setting is increasing, only one instance of its use with D5W for an entrapment neuropathy has been reported.²²

In the study reported here, we hypothesized that ultrasound-guided PIT with D5W is effective for treatment of CTS. We conducted an investigation of the 6-month effect of this treatment in patients who had mild-to-moderate CTS.

MATERIALS AND METHODS

Study Design

The present investigation was a prospective, randomized, placebo-controlled, and double-blind study conducted at a single medical center in Taiwan between May 1, 2016, through March 30, 2017. With the review and approval of the Institutional Review Board of Tri-Service General Hospital (No. 2-105-05-033), all enrolled participants provided written and fully informed consent. A total of 60 patients diagnosed with mild-to-moderate CTS were assessed for eligibility, and 49 were enrolled in our study. The patients were assigned to either a D5W group or a control group, using a block randomization (1:1 ratio) based on computer-generated random numbers in Microsoft Excel. The D5W patient group received 1 session of ultrasound-guided PIT, with 5 cc of D5W; the control group received ultrasound-guided PIT with 5 cc of normal saline. For patients who had bilateral CTS, both wrists were assigned to the same treatment group. All patients were prohibited from receiving

any other conservative management for CTS from 2 weeks before the start of participation to the end of the study. Only acetaminophen (500 mg up to 4 g daily) was allowed as a pain-relief agent. To ensure adherence to this restriction, a study nurse regularly followed up with patients.

Inclusion and Exclusion Criteria

Patients who were diagnosed with mild-to-moderate CTS on the basis of an electrophysiological analysis, and who had onset symptoms that had persisted for at least 6 months, were considered for inclusion. The criteria for clinical symptoms and signs used for diagnosis are defined in Table 1. A diagnosis of CTS was assigned to patients who met inclusion criterion 1 and one or more of inclusion criteria 2-4.^{23,24} Exclusion criteria are defined in Table 1 as well.^{25,26}

Electrophysiological Analysis and CTS Grading

The diagnosis and grading of CTS were made on the basis of an electrophysiological study (Table 2).²⁷⁻²⁹ Only patients who had mild-to-moderate CTS were recruited.

Ultrasound-guided PIT

Ultrasound-guided injection was performed as previously described, using MyLab™25Gold(Esaote).²⁶ The MN was assessed at the proximal carpal tunnel inlet (ie, the scaphoid-pisiform level). The ultrasound-guided PIT, with 5 cc of either D5W or normal saline, was performed using an in-plane ulnar approach. A 3-ml injectate was used to remove the nerve from the flexor retinaculum via hydrodissection, and a residual

TABLE 1. Inclusion and Exclusion Criteria

Inclusion criteria

1. Paresthesia/dysesthesia; painful swelling with clumsy weakness of the hand, exacerbated by sleep or repetitive use of the wrist, and relieved by shaking the hand, with postural change
2. Sensory loss with numbness in the median nerve—innervated regions of the hand
3. Weakness with atrophy of the median nerve—innervated thenar muscles
4. Positive Phalen test and/or Tinel sign

Exclusion criteria

1. History of polyneuropathy, brachial plexopathy, or thoracic outlet syndrome
2. Previous wrist surgery or steroid injection for carpal tunnel syndrome

TABLE 2. Electrophysiological Study and Grades of Carpal Tunnel Syndrome

- Cut-off points or normal value
1. Upper limit of distal latency of median sensory nerve ≤ 3.6 ms at a distance of approximately 14 cm from the active electrode
 2. Upper limit of DML of the median nerve < 4.3 ms at a distance of approximately 8 cm from the thenar muscle

Grade

3. Minimal: abnormal segmental or comparative tests only
4. Mild: abnormal digit/wrist sensory nerve conduction velocity only, with normal DML
5. Moderate: abnormal digit/wrist sensory nerve conduction velocity and abnormal DML
6. Severe: absence of sensory response and abnormal DML
7. Extreme: absence of motor and sensory responses

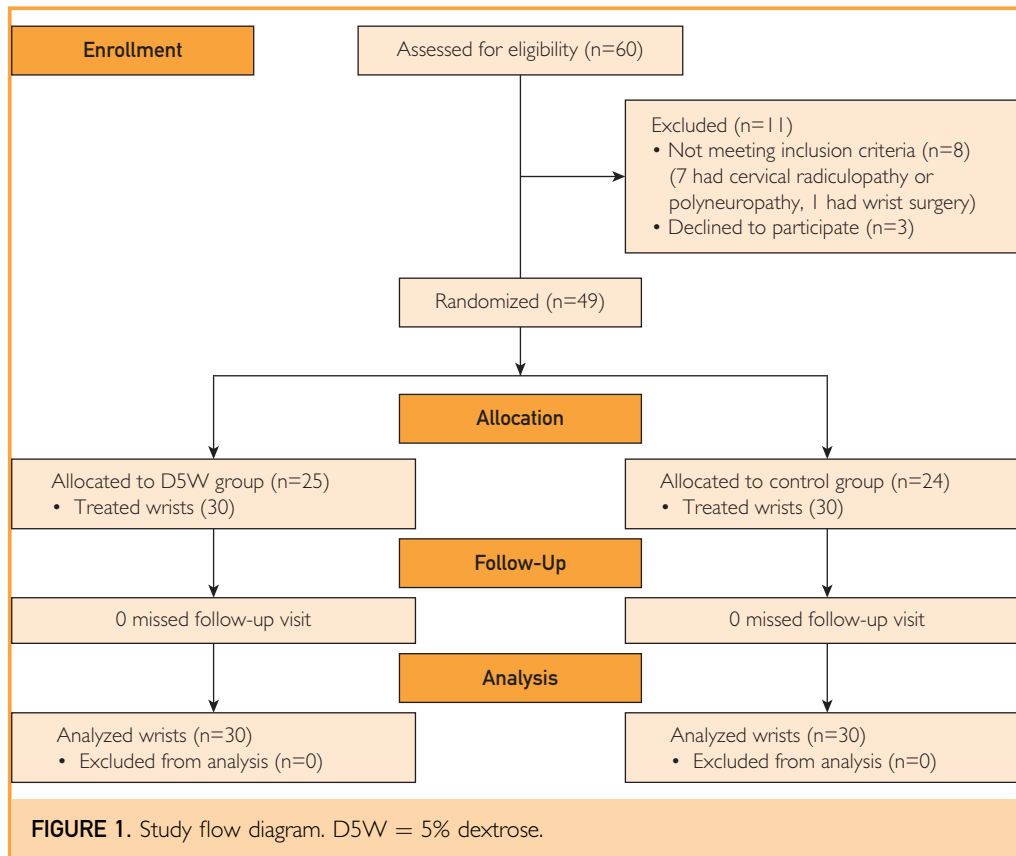
DML = distal motor latency.

2-ml injectate was delivered to the inferior part of the MN for separation from the underlying subsynovial connective tissue and flexor tendons. After injection, the whole carpal tunnel was scanned to ensure that the injectate was distributed throughout the proximal-to-distal carpal tunnel. Every patient was monitored for 30 minutes after injection for possible complications, such as bleeding and nerve trauma.

Outcome Measurements

The same physiatrist performed all outcome assessments, without knowledge of which group patients were in or the injectate content, at 1, 3, and 6 months post-injection, for comparison with pre-injection measures.

Primary Outcome: Visual Analog Scale (VAS) Score. The VAS was used to assess digital pain severity and paresthesia/dyesthesia



within 1 week before evaluation.²⁶ Scores ranged from 10 (extremely severe pain) to 0 (no pain) points.³⁰

Secondary Outcome: Boston Carpal Tunnel Syndrome Questionnaire (BCTQ) Score. The self-administered BCTQ includes 2 subscales of symptom severity (11 questions) and functional status (8 questions); it is the most commonly used measurement for CTS.³¹ Scores range from 0 to 5 points for each question, with higher scores indicating greater severity and dysfunction.

Secondary Outcome: Cross-sectional Area (CSA) of the MN. The same physiatrist measured the CSA of the MN as described elsewhere.^{25,26} In brief, the CSA was measured using an electronic caliper at the proximal inlet of the carpal tunnel (ie, at the scaphoid-pisiform level). The mean of 3 such measurements was used for analysis.

Secondary Outcome: Electrophysiological Analysis Results. The antidromic sensory nerve conduction velocity (SNCV) and distal

motor latency (DML) of the MN were measured in all patients as described elsewhere.^{26,32} In brief, the SNCV was measured using a 14-cm stimulator that was proximal to the active electrode over the second interphalangeal joint. The DML was recorded via MN stimulation at 8 cm proximal to the active electrode over the abductor pollicis brevis muscle. An average of 3 such measurements was calculated.

Secondary Outcome: Global Assessment of Treatment Results. At the 3- and 6-month follow-up assessments, symptom relief after injection was evaluated for all patients and categorized as one of the following: much improved, improved, no change, worse, or much worse. Patients in the category of much improved or improved were considered to have had effective treatment.

Sample Size

A preliminary power analysis using G*power 3.1.9.2 (University of California, Los Angeles) was calculated in a repeated-measures 1-way analysis of variance for comparison of 2 groups. For an effect size ranging from

TABLE 3. Baseline Demographic and Clinical Characteristics of Study Participants^a

Characteristic	5% dextrose group (n=30)	Control group (n=30)	P value ^b
Age (y)	58.47±2.33	58.10±1.93	.90
Body height (cm)	158.13±1.20	160.17±1.01	.20
Body weight (kg)	65.13±1.69	62.77±1.35	.28
Diabetes mellitus	2 (6.67)	4 (13.33)	.67
Hypertension	14 (46.67)	16 (53.33)	.80
Gender			.73
Male	4 (13.33)	6 (20.00)	
Female	26 (86.67)	24 (80.00)	
Duration (mo)	44.57±7.54	44.47±5.53	.99
Lesion site			.61
Right	17 (56.67)	14 (46.67)	
Left	13 (43.33)	16 (53.33)	
Grading (Padua)			.99
Moderate	19 (63.33)	18 (60.00)	
Mild	11 (36.67)	12 (40.00)	
Visual analog scale	6.67±0.30	6.56±0.30	.81
Boston Carpal Tunnel Syndrome Questionnaire score			
Severity	30.20±1.25	28.07±1.93	.36
Function	21.87±0.69	19.93±0.96	.11
Sensory nerve conduction velocity (m/s)	33.76±1.01	33.83±0.90	.96
Distal motor latency (ms)	4.89±0.24	4.68±0.15	.45
Cross-sectional area (mm ²)	12.36±0.35	12.29±0.36	.89

^aValues are given as No. (%), or ± standard error.

^bP value obtained from independent t-test for continuous data, and χ^2 test/Fisher exact test for categorical data.

0.5 to 0.25, data for at least 16 to 54 wrists were required to achieve sufficient power [(1-β)=0.95; α=0.05].³³

Statistical Analyses

All data were analyzed using IBM SPSS software, version 22. Demographic data were analyzed using an independent *t*-test for continuous data, and a χ² test or Fisher exact test for categorical data. A repeated-measures analysis of variance and a subsequent post hoc test were used for analysis of the follow-up data. An independent *t*-test was performed to compare differences between groups, including VAS scores, BCTQ scores, CSA of MN measurements, electrophysiological study

results, and global assessment results. All statistical tests were 2-tailed; a *P* value of less than .05 was considered statistically significant.

RESULTS

A total of 49 participants completed the study, yielding data from 30 wrists in each group (Figure 1). Clinical characteristics of the participants did not differ between groups (Table 3; all *P*>.05). The mean duration of symptom onset was 44.57±7.54 and 44.47±5.53 months in the D5W and control groups, respectively. More than 60% of the wrists in each group had a moderate CTS grade. Table 4 presents the VAS and BCTQ

TABLE 4. All Measurements in Both Groups, Before and After Injection^a

	5% dextrose group (n=30)		Control group (n=30)	
	Mean ± standard error	<i>P</i> value	Mean ± standard error	<i>P</i> value ^b
Visual analog scale score				
Before injection	6.67±0.30		6.56±0.30	
M1	4.60±0.35	<.001	5.64±0.35	.002
M3	3.57±0.30	<.001	4.70±0.46	<.001
M6	2.43±0.30	<.001	4.59±0.46	<.001
Boston Carpal Tunnel Syndrome Questionnaire score—severity				
Before injection	30.20±1.25		28.07±1.93	
M1	20.83±1.06	<.001	22.37±1.76	<.001
M3	17.60±0.80	<.001	20.50±2.02	<.001
M6	15.30±0.60	<.001	21.60±2.06	.002
Boston Carpal Tunnel Syndrome Questionnaire score—function				
Before injection	21.87±0.69		19.93±0.96	
M1	14.17±0.72	<.001	18.00±1.05	.09
M3	12.90±0.52	<.001	16.77±1.18	.005
M6	11.43±0.46	<.001	17.07±1.23	.03
Sensory nerve conduction velocity (m/s)				
Before injection	33.76±1.01		33.83±0.90	
M1	35.46±1.17	.04	34.08±0.91	.99
M3	36.29±1.06	.003	33.72±1.03	.99
M6	36.75±1.19	.004	34.08±1.04	.99
Distal motor latency (ms)				
Before injection	4.89±0.24		4.68±0.15	
M1	4.68±0.23	.22	4.72±0.15	.99
M3	4.64±0.22	.20	4.72±0.15	.99
M6	4.53±0.20	.43	4.64±0.16	.99
Cross-sectional area (mm ²)				
Before injection	12.36±0.35		12.29±0.36	
M1	11.00±0.33	<.001	11.32±0.37	<.001
M3	10.53±0.31	<.001	11.22±0.37	<.001
M6	10.26±0.35	<.001	11.11±0.38	<.001

^aM = month.

^b*P* value obtained from repeated-measures analysis of variance and subsequent post hoc test.

scores, electrophysiological results, and the CSA of the MN, before and after injection. The VAS and BCTQ scores and CSA measurements in both groups indicated notable improvement at all follow-up time points, compared with baseline measures (all $P < .05$; not including the first-month BCTQ function of the control group [$P = .08$]). For the electrophysiological analysis, only the SNCV results for the D5W group were significant at all follow-up time points, compared with baseline ($P < .05$), although we observed a tendency toward improvement in the DML of the D5W group at follow-up time points further from injection.

Compared with the scores of the control group, at all follow-up time points, the D5W group scores for VAS, BCTQ severity, and BCTQ function (all scores reported as D5W group vs control group, respectively) revealed significant improvement. For VAS (Figure 2), scores were: -2.07 ± 0.24 vs -0.93 ± 0.21 at 1 month; $P = .001$; -3.10 ± 0.35 vs -1.86 ± 0.37 at 3 months; $P = .02$; and -4.23 ± 0.33 vs -1.98 ± 0.37 at 6 months; $P < .001$. For BCTQ severity (Figure 3A),

scores were: -9.37 ± 1.20 vs -5.70 ± 0.93 at 1 month; $P = .02$; -12.60 ± 1.19 vs -7.57 ± 1.54 at 3 months; $P = .01$; and -14.90 ± 1.24 vs -6.47 ± 1.46 at 6 months; $P < .001$. For BCTQ function (Figure 3B), scores were: -7.70 ± 0.97 vs -1.93 ± 0.65 at 1 month; $P < .001$; -8.97 ± 0.73 vs -3.17 ± 0.79 at 3 months; $P < .001$; and -10.43 ± 0.83 vs -2.87 ± 0.86 at 6 months; $P < .001$. These effects became more pronounced as the follow-up duration increased.

The SNCV, DML, and CSA differences between the 2 groups were also significant (Table 5), with the exception of (D5W group vs control group, respectively) the DML at 6 months (-0.37 ± 0.20 ms vs -0.04 ± 0.07 ms; $P = .12$) and the CSA at 1 month (-1.37 ± 0.19 mm² vs -0.97 ± 0.13 mm²; $P = .09$). In addition, 70% (21 of 30) and 50% (15 of 30) of patients scored a grade of either much improved or improved at the follow-up at 3 months in the D5W and control groups, respectively ($P = .11$). These proportions increased to 76% (23 of 30) and 40% (12 of 30), respectively, at the follow-up at 6 months ($P = .004$; data not shown). No adverse effects, complications, or nerve trauma were observed in either group. All patients reported that they had not received any extra medication or treatment during the study.

DISCUSSION

The present study is the first prospective, randomized, double-blind, placebo-controlled study to investigate the benefit of ultrasound-guided PIT with D5W for mild-to-moderate CTS. Compared with controls, the D5W group exhibited a significant reduction in pain and disability, an improved electrophysiological response, and a decreased CSA of the MN for 6 months after treatment.

The D5W solution is the most commonly used injectate for PIT; however, to date, only 2 case series studies and 1 small clinical trial of D5W use have been reported.⁶⁻⁸ Kim et al⁶ reported that at a follow-up at 7 days, myofascial trigger-point injection therapy with D5W was superior to that using lidocaine or normal saline. Dufour et al¹² first used ultrasound-guided circumferential PIT with D5W at the MN before an intravascular local anesthetic injection for elbow surgery. They reported that additional D5W did not change the amount of

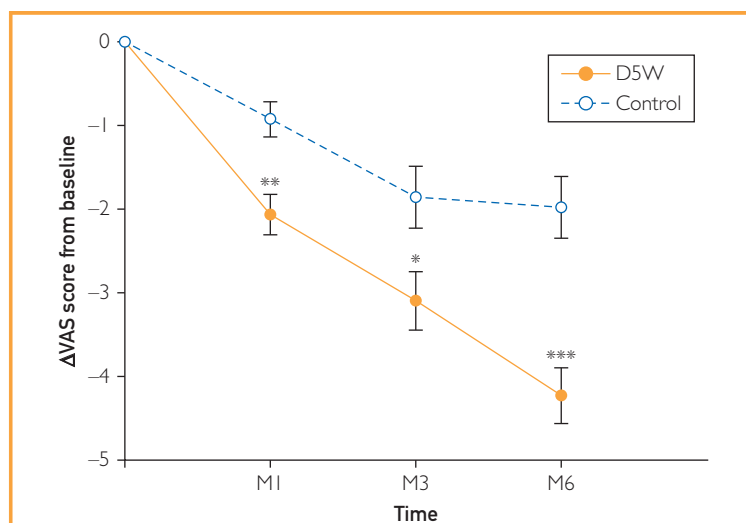


FIGURE 2. Mean change at baseline and post-injection in visual analog scale results in both groups (mean \pm standard error). The visual analog scale scores were significantly lower in the 5% dextrose group than in the control group, at all follow-up assessments ($P < .05$), and this reduction became more pronounced as the follow-up duration increased. * $P < .05$; ** $P < .01$; *** $P < .001$; an independent *t*-test was used. D5W = 5% dextrose; M = month; VAS = visual analog scale.

time before anesthesia was needed. Unfortunately, the therapeutic effect of D5W was not measured in their study. Although physicians increasingly use PIT, the use of ultrasound-guided PIT with D5W rarely has been reported.²² Chang et al²² first used ultrasound-guided PIT with D5W to treat a case involving entrapment of the superficial radial nerve branch, but they did not report the duration of therapy. Our systematic study is the first to report the effectiveness of PIT with D5W for peripheral entrapment neuropathy.

The mechanism underlying the effects of PIT with D5W is unknown and may be multifactorial. Dextrose can reduce neurogenic inflammation via the inhibition of capsaicin-sensitive receptors (eg, transient receptor potential vanilloid receptor-1) to stop the secretion of both substance P and calcitonin gene-related peptide, which are known to induce pain and swelling of the nerve and/or surrounding tissue.³⁴⁻³⁹ However, various concentrations of dextrose have been used, and no study has specifically investigated the mechanism of D5W treatment. Future studies should use a histological analysis of a CTS animal model.

Nerve hydrodissection may also contribute to the therapeutic effects of D5W. Nerve hydrodissection is used to avoid nerve trauma and detach soft tissues, increasing the passage of nerve impulses and limiting ischemic nerve damage.^{26,40} Recently, hydrodissection was used to assist ultrasound-guided nerve injection with corticosteroid in combination with lidocaine or platelet-rich plasma in patients who have CTS,^{15,16,26} cubital tunnel syndrome,¹⁷ meralgia paresthetica,^{18,19} or infrapatellar saphenous neuralgia.²⁰ Although hydrodissection is used pervasively in clinical practice, hydrodissection research has involved only a small number of participants, or has lacked a control group or randomization, leading to selection bias. In addition, most of the analgesic improvement could result from the well-established analgesic effect of corticosteroid, lidocaine, and platelet-rich plasma.^{26,41} Hence, the effect of and optimal time point for performing nerve hydrodissection are currently unknown.⁴⁰

Our study design, which includes a consistent injection procedure and injectate volume, could eliminate the confounding effects of hydrodissection. In addition, our control group

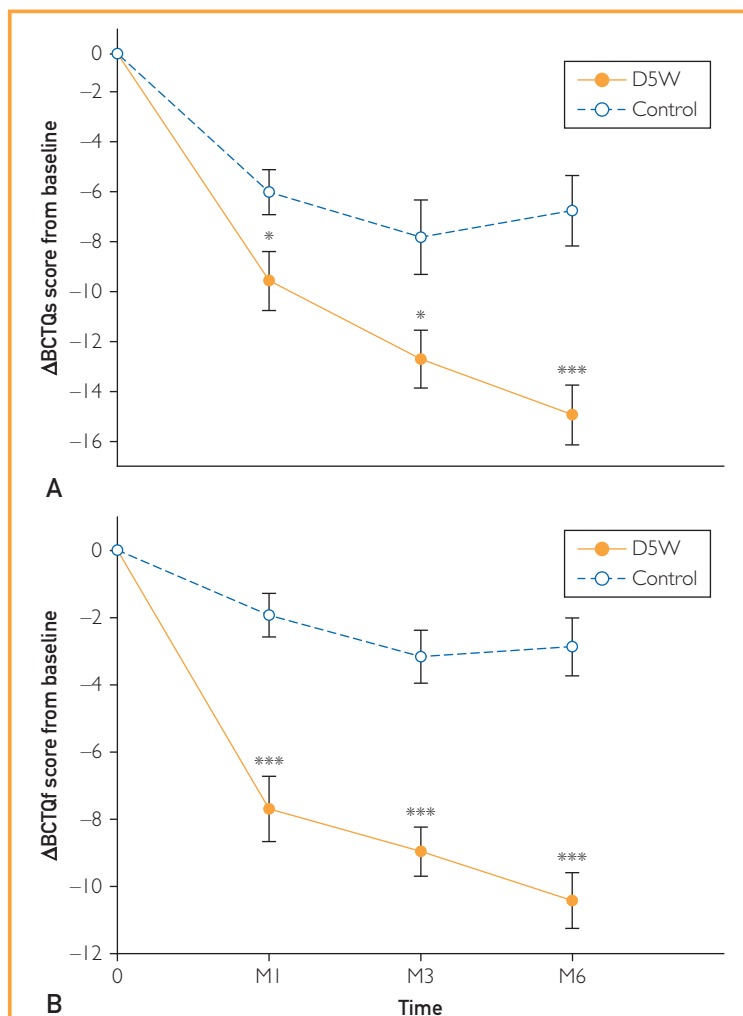


FIGURE 3. Mean difference at baseline and post-injection in Boston Carpal Tunnel Syndrome Questionnaire (BCTQ) scores in both groups (mean \pm standard error). (A) The BCTQ (severity) scores were significantly lower, indicating improvement, in the 5% dextrose group, compared with the control group, at all follow-up assessments ($P < .05$). (B) The BCTQ (function) scores were significantly lower, indicating improvement, in both groups, at all follow-up assessments ($P < .001$). All differences became more pronounced as the follow-up duration increased. * $P < .05$; ** $P < .01$; *** $P < .001$; an independent t-test was used. BCTQf = BCTQ function; BCTQs = BCTQ severity; D5W = 5% dextrose; M = month.

was treated with normal saline because it has no pharmacologic effect on nerves. The effects we report persisted for 6 months, indicating the substantial efficacy of only 1 session of D5W treatment for mild-to-moderate CTS. Further, the improvement reflected by VAS and BCTQ scores, electrophysiological responses, and CSA in the D5W group, compared with the

TABLE 5. Between-Group Comparison of Pretreatment Changes in Electrophysiological Study Results and Cross-sectional Area^a

	5% dextrose group (n=30)	Control group (n=30)	P value ^b
	Mean difference ± standard error	Mean difference ± standard error	
Sensory nerve conduction			
velocity (m/s)			
M1	1.70±0.58	0.25±0.29	.03
M3	2.53±0.65	-0.11±0.32	.001
M6	2.98±0.79	0.25±0.33	.003
Distal motor latency (ms)			
M1	-0.22±0.10	0.03±0.06	.04
M3	-0.26±0.11	0.03±0.05	.03
M6	-0.37±0.20	-0.04±0.07	.12
Cross-sectional area (mm ²)			
M1	-1.37±0.19	-0.97±0.13	.09
M3	-1.83±0.24	-1.07±0.16	.01
M6	-2.11±0.26	-1.18±0.18	.004

^aM = month.
^bP value was obtained from independent t-test.

baseline time point and control group, appeared to increase with follow-up (Table 5; Figures 2 and 3). The effects of our D5W treatment likely would be maintained with further follow-up. Compared with corticosteroid (the most popular injectate for CTS), D5W can be used for a longer period and with fewer adverse effects; an evidence-based study reported that local corticosteroid injection was effective for only 1 month for CTS, compared with placebo control.⁴¹ These 2 injectates should be compared in future studies.

We found considerable improvement in VAS, BCTQ, and CSA results in the control group, compared with baseline, suggesting that the therapeutic effect of 1 session of nerve hydrodissection with normal saline persists for 6 months. However, a placebo effect associated with injection, and spontaneous remission of CTS, could have occurred. Some randomized clinical trials have used a blind design to investigate the effects of corticosteroid injection for CTS compared with a normal saline or lidocaine control. The reported placebo effects for these studies ranged from 20% (10 mg lidocaine, follow-up assessment at 1 month) to 34% (1 cc normal saline + 1 cc lidocaine, follow-up assessment at 2 weeks).^{42,43} Three trials have used only normal saline with a blind injection of a control group. Karadaş et al⁴⁴ did not observe any improvement with 1 cc of normal saline.

Peters-Veluthamaningal et al⁴⁵ found that 5 of 33 (15%) patients exhibited a satisfactory partial response at a follow-up assessment at 1 week after a 1-cc normal saline injection. Girlanda et al⁴⁶ reported notable improvement in nocturnal paresthesia and motor action potential at up to 2 months after a 15-mg normal saline injection (9 mg/cc; 2 injection sessions with a 1-week intervening interval).

The effect of normal saline injection in our study was longer and more pronounced, compared with the effects in the aforementioned research, possibly owing to differences in the guided method or injectate volume. Our study was the first to use ultrasound-guided injection with normal saline for the control group, and the 5 cc of injectate was a greater volume than that used in previous studies. A direct compression of the transverse carpal ligament at the MN induces CTS, and CTS subsequently induces inflammation of the intracarpal tendon. This condition commonly causes a cycle of swelling within the carpal tunnel and further compresses the MN.⁴⁷ Moreover, compared with blind injection, ultrasound-guided nerve hydrodissection is better for removing surrounding tissues from the MN, especially the intracarpal tendons. Nevertheless, 34% of untreated patients can spontaneously improve after 10-15 months of follow-up.⁴⁸ For our patients, the mean duration of

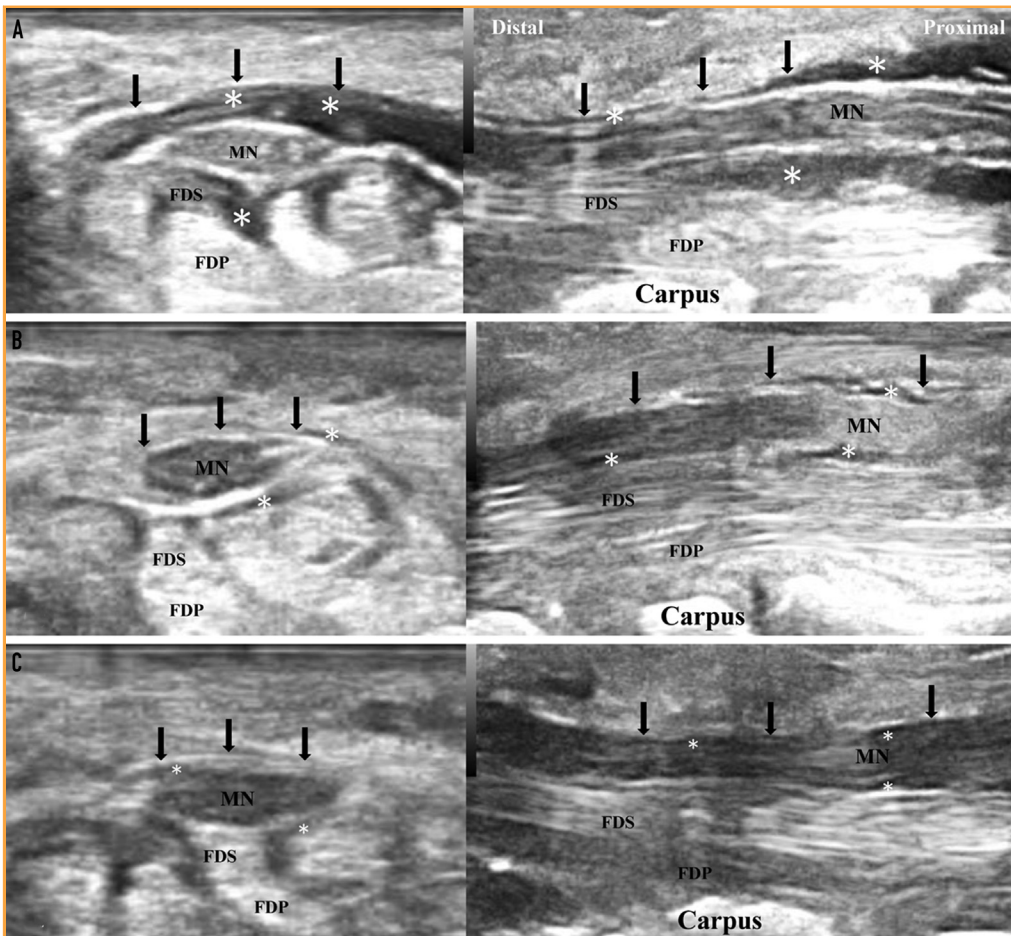


FIGURE 4. Follow-up ultrasonography imaging after injection (left: transverse view; right: long axial view). (A) Immediately after injection: The injectate (*) can be observed between the flexor retinaculum (arrows), median nerve, and flexor tendons. (B) Thirty minutes after injection: Most injectate (*) is absorbed. (C) One hour after injection: The injectate (*) is completely absorbed. FDP = flexor digitorum profundus; FDS = flexor digitorum superficialis; MN = median nerve.

symptom onset for both groups was 44 months, and the rate of spontaneous remission was relatively low. Most were first diagnosed with CTS at the time of our study and therefore retain the potential for spontaneous remission. We observed that the injectate was completely absorbed at 1 hour after injection, followed by ultrasonography (Figure 4). Consequently, the effects of 1-session nerve hydrodissection with normal saline could have been overestimated in our study. We are conducting a double-blind study, using an ultrasound-guided subcutaneous injection of normal saline for control participants, to investigate the effects of nerve hydrodissection.

Limitations

Our study has some limitations. First, we did not evaluate the mechanism of the effects of D5W. Second, we were not able to determine the influence or most appropriate timing of nerve hydrodissection. Our ongoing clinical trials with a sham-controlled design may provide relevant information. Finally, the optimal dosage and number of PIT sessions is unknown, so further studies are needed.

CONCLUSION

Our study reveals that ultrasound-guided PIT with D5W is a simple, safe, and effective treatment for mild-to-moderate CTS. Moreover,

this technique may be valuable for treating neuropathic pain and other peripheral entrapment neuropathies.

ACKNOWLEDGMENTS

The authors are grateful to Miss Jennifer Hsu, BS, who provided technical assistance and enabled the completion of this study.

Abbreviations and Acronyms: BCTQ = Boston Carpal Tunnel Syndrome Questionnaire; CSA = cross-sectional area; CTS = carpal tunnel syndrome; D5W = 5% dextrose; DML = distal motor latency; MN = median nerve; PIT = perineural injection therapy; SNCV = sensory nerve conduction velocity; VAS = visual analog scale

Correspondence: Address to Liang-Cheng Chen, MD, Department of Physical Medicine and Rehabilitation, Tri-Service General Hospital, School of Medicine, National Defense Medical Center, No 325, Sec 2, Cheng-Kung Road, Neihu District, Taipei, Taiwan, Republic of China (clctsg@yaho.com.tw).

REFERENCES

- Atroshi I, Gummesson C, Johnsson R, Ormstein E, Ranstam J, Rosén I. Prevalence for clinically proved carpal tunnel syndrome is 4 percent. *Lakartidningen*. 2000;97(14):1668-1670.
- Bland JD, Rudolfer SM. Clinical surveillance of carpal tunnel syndrome in two areas of the United Kingdom, 1991-2001. *J Neurol Neurosurg Psychiatry*. 2003;74(12):1674-1679.
- Aroori S, Spence RA. Carpal tunnel syndrome. *Ulster Med J*. 2008;77(1):6-17.
- DeStéfano F, Nordstrom DL, Vierkant RA. Long-term symptom outcomes of carpal tunnel syndrome and its treatment. *J Hand Surg Am*. 1997;22(2):200-210.
- O'Connor D, Marshall S, Massy-Westropp N. Non-surgical treatment (other than steroid injection) for carpal tunnel syndrome. *Cochrane Database Syst Rev*. 2003;(1):CD003219.
- Kim MY, Na YM, Moon JH. Comparison on treatment effects of dextrose water, saline, and lidocaine for trigger point injection. *J Korean Acad Rehabil Med*. 1997;21(5):967-973.
- Weglein AD. Neural prolotherapy. *Journal of Prolotherapy*. 2011;3(2):639-643.
- Conaway E, Browning B. Neural prolotherapy for neuralgia. *J Prolother*. 2014;6:e928-e931.
- Tsui BC, Kropelin B. The electrophysiological effect of dextrose 5% in water on single-shot peripheral nerve stimulation. *Anesth Analg*. 2005;100(6):1837-1839.
- Hashimoto K, Sakura S, Bollen AW, Ciriales R, Drasner K. Comparative toxicity of glucose and lidocaine administered intrathecally in the rat. *Reg Anesth Pain Med*. 1998;23(5):444-450.
- Sakura S, Chan VW, Ciriales R, Drasner K. The addition of 7.5% glucose does not alter the neurotoxicity of 5% lidocaine administered intrathecally in the rat. *Anesthesiology*. 1995;82(1):236-240.
- Dufour E, Donat N, Jaziri S, et al. Ultrasound-guided perineural circumferential median nerve block with and without prior dextrose 5% hydrodissection: a prospective randomized double-blinded noninferiority trial. *Anesth Analg*. 2012;115(3):728-733.
- Jensen KT, Rabago DP, Best TM, Patterson JJ, Vanderby R Jr. Early inflammatory response of knee ligaments to prolotherapy in a rat model. *J Orthop Res*. 2008;26(6):816-823.
- Covey CJ, Sineath MH Jr, Penta JF, Leggit JC. Prolotherapy: can it help your patient? *J Fam Pract*. 2015;64(12):763-768.
- Smith J, Wisniewski SJ, Finnoff JT, Payne JM. Sonographically guided carpal tunnel injections: the ulnar approach. *J Ultrasound Med*. 2008;27(10):1485-1490.
- DeLea SL, Chavez-Chiang NR, Poole JL, Norton HE, Sibbitt WL Jr, Bankhurst AD. Sonographically guided hydrodissection and corticosteroid injection for scleroderma hand. *Clin Rheumatol*. 2011;30(6):805-813.
- Choi CK, Lee HS, Kwon JY, Lee WJ. Clinical implications of real-time visualized ultrasound-guided injection for the treatment of ulnar neuropathy at the elbow: a pilot study. *Ann Rehabil Med*. 2015;39(2):176-182.
- Mulvaney SW. Ultrasound-guided percutaneous neuroplasty of the lateral femoral cutaneous nerve for the treatment of meralgia paresthetica: a case report and description of a new ultrasound-guided technique. *Curr Sports Med Rep*. 2011;10(2):99-104.
- Tagliafico A, Serafini G, Lacelli F, Perrone N, Valsania V, Martinoli C. Ultrasound-guided treatment of meralgia paresthetica (lateral femoral cutaneous neuropathy): technical description and results of treatment in 20 consecutive patients. *J Ultrasound Med*. 2011;30(10):1341-1346.
- Clendenen S, Greengrass R, Whalen J, O'Connor MI. Infrapatellar saphenous neuralgia after TKA can be improved with ultrasound-guided local treatments. *Clin Orthop Relat Res*. 2015;473(1):119-125.
- Fader RR, Mitchell JJ, Chadayammuri VP, Hill J, Wolcott ML. Percutaneous ultrasound-guided hydrodissection of a symptomatic sural neuroma. *Orthopedics*. 2015;38(11):e1046-e1050.
- Chang KV, Hung CY, Özçakar L. Snapping thumb and superficial radial nerve entrapment in De Quervain disease: ultrasound imaging/guidance revisited. *Pain Med*. 2015;16(11):2214-2215.
- Jablecki CK, Andary MT, Floeter MK, et al. American Association of Electrodiagnostic Medicine, American Academy of Neurology, American Academy of Physical Medicine and Rehabilitation. Practice parameter: electrodiagnostic studies in carpal tunnel syndrome. *Neurology*. 2002;58(11):1589-1592.
- You H, Simmons Z, Freivalds A, Kothari MJ, Naidu SH. Relationships between clinical symptom severity scales and nerve conduction measures in carpal tunnel syndrome. *Muscle Nerve*. 1999;22(4):497-501.
- Wu YT, Ke MJ, Chou YC, et al. Effect of radial shock wave therapy for carpal tunnel syndrome: a prospective randomized, double-blind, placebo-controlled trial. *J Orthop Res*. 2016;34(6):977-984.
- Wu YT, Ho TY, Chou YC, et al. Six-month efficacy of platelet-rich plasma for carpal tunnel syndrome: a prospective randomized, single-blind controlled trial. *Sci Rep*. 2017;7(1):94.
- Rossi S, Giannini F, Passero S, Paradiso C, Battistini N, Cioni R. Sensory neural conduction of median nerve from digits and palm stimulation in carpal tunnel syndrome. *Electroencephalogr Clin Neurophysiol*. 1994;93(5):330-334.
- Padua L, Lo Monaco M, Valente EM, Tonalì PA. A useful electrophysiologic parameter for diagnosis of carpal tunnel syndrome. *Muscle Nerve*. 1996;19(1):48-53.
- Padua L, Lo Monaco M, Gregori B, Valente EM, Padua R, Tonalì P. Neurophysiological classification and sensitivity in 500 carpal tunnel syndrome hands. *Acta Neurol Scand*. 1997;96(4):211-217.
- Huskisson EC. Measurement of pain. *Lancet*. 1974;2(7889):1127-1131.
- Levine DW, Simmons BP, Koris MJ, et al. A self-administered questionnaire for the assessment of severity of symptoms and functional status in carpal tunnel syndrome. *J Bone Joint Surg Am*. 1993;75(11):1585-1592.
- Jablecki CK, Andary MT, So YT, Wilkins DE, Williams FH, AAEM Quality Assurance Committee. Literature review of the usefulness of nerve conduction studies and

- electromyography for the evaluation of patients with carpal tunnel syndrome. *Muscle Nerve*. 1993;16(12):1392-1414.
33. Faul F, Erdfelder E, Lang AG, Buchner A. G*Power 3: a flexible statistical power analysis program for the social, behavioral, and biomedical sciences. *Behav Res Methods*. 2007;39(2):175-191.
 34. Yelland MJ, Sweeting KR, Lyftogt JA, Ng SK, Scuffham PA, Evans KA. Prolotherapy injections and eccentric loading exercises for painful Achilles tendinosis: a randomised trial. *Br J Sports Med*. 2011;45(5):421-428.
 35. Rabago D, Patterson JJ, Mundt M, et al. Dextrose prolotherapy for knee osteoarthritis: a randomized controlled trial. *Ann Fam Med*. 2013;11(3):229-237.
 36. Bertrand H, Kyriazis M, Reeves KD, Lyftogt J, Rabago D. Topical mannitol reduces capsaicin-induced pain: results of a pilot-level, double-blind, randomized controlled trial. *PM R*. 2015;7(11):1111-1117.
 37. Murakawa Y, Zhang W, Pierson CR, et al. Impaired glucose tolerance and insulinopenia in the GK-rat causes peripheral neuropathy. *Diabetes Metab Res Rev*. 2002;18(6):473-483.
 38. Zamami Y, Takatori S, Yamawaki K, et al. Acute hyperglycemia and hyperinsulinemia enhance adrenergic vasoconstriction and decrease calcitonin gene-related peptide-containing nerve-mediated vasodilation in pithed rats. *Hypertens Res*. 2008;31(5):1033-1044.
 39. Wei Z, Wang L, Han J, et al. Decreased expression of transient receptor potential vanilloid 1 impairs the postischemic recovery of diabetic mouse hearts. *Circ J*. 2009;73(6):1127-1132.
 40. Cass SP. Ultrasound-guided nerve hydrodissection: what is it? A review of the literature. *Curr Sports Med Rep*. 2016;15(1):20-22.
 41. Marshall S, Tardif G, Ashworth N. Local corticosteroid injection for carpal tunnel syndrome. *Cochrane Database Syst Rev*. 2007;(2):CD001554.
 42. Dammers JW, Veering MM, Vermeulen M. Injection with methylprednisolone proximal to the carpal tunnel: randomised double blind trial. *BMJ*. 1999;319(7214):884-886.
 43. Armstrong T, Devor W, Borschel L, Contreras R. Intracarpal steroid injection is safe and effective for short-term management of carpal tunnel syndrome. *Muscle Nerve*. 2004;29(1):82-88.
 44. Karadaş Ö, Tok F, Akarsu S, Tekin L, Balaban B. Triamcinolone acetonide vs procaine hydrochloride injection in the management of carpal tunnel syndrome: randomized placebo-controlled study. *J Rehabil Med*. 2012;44(7):601-604.
 45. Peters-Veluthamaningal C, Winters JC, Groenier KH, Meyboom-de Jong B. Randomised controlled trial of local corticosteroid injections for carpal tunnel syndrome in general practice. *BMC Fam Pract*. 2010;11:54.
 46. Girlanda P, Dattola R, Venuto C, Mangiapane R, Nicolosi C, Messina C. Local steroid treatment in idiopathic carpal tunnel syndrome: short- and long-term efficacy. *J Neurol*. 1993;240(3):187-190.
 47. Karadaş Ö, Tok F, Ulaş UH, Odabaşı Z. The effectiveness of triamcinolone acetonide vs. procaine hydrochloride injection in the management of carpal tunnel syndrome: a double-blind randomized clinical trial. *Am J Phys Med Rehabil*. 2011;90(4):287-292.
 48. Padua L, Padua R, Aprile I, Pasqualetti P, Tonali P; Italian CTS Study Group. Carpal tunnel syndrome. Multiperspective follow-up of untreated carpal tunnel syndrome: a multicenter study. *Neurology*. 2001;56(11):1459-1466.